International Journal of
Scientific Engineering and Technology Research

ISSN 2319-8885
Vol.04,Issue.12,
May-2015,
Pages:2263-2268

www.ijsetr.com

Tongue Image Analysis for Medical Diagnosis

TINA LIDIA J[1], PROF. HUSSAIN AHMED[2]
[1]PG Scholar, Dept of Electronics, HKBK College of Engineering, Nagawara, Bangalore, Karnataka, India,
E-mail: teena_clement@yahoo.co.in.
[2]HOD, Dept of Electronics & Communication, HKBK College of Engineering, Nagawara, Bangalore, Karnataka, India,
E-mail: hussainahmedsaleh@gmail.com.

Abstract: The paper finds a user friendly way of detecting whether a person is positive with diabetes or not. In this paper the tongue images that are captured from a person serves as a way to detect if the person is diabetic or not. This is a first time, in medical imaging that this type of test is been suggested, this could prevent time and mental tension of the patients. The tongue image is captured and based on this concept the image is analyzed in terms of color, texture and geometric feature. To combat the conventional methods this paper proposes a method to avoid the introduction of instruments in the patient body to detect diabetes mellitus (DM) and non-proliferative diabetic retinopathy (NPDR) .A noninvasive device is used for this , the images that are captured are image wrapped , a tongue color spectrum is established with 12 color which could be present on the tongue , the tongue texture is identified with the using the predicted texture values in which one of the value close to the prediction is represented by the eight blocks that would characterize them . Finally the geometric details are calculated based on the 13 features that are extracted from the tongue images based on the measurement, distance, area and their ratio. The combination of the color, texture and geometry of the tongue would help us analyze the health condition of the patient and categorize them into three categories.

Keywords: Diabeties Mellitus, Diabetic Retinopathy, Tongue Segmentation, Tongue Geometry.

I. INTRODUCTION

We being in the 20th century medical diagnosis is improving day by day and so are the various types of disease. The next generation trend is that people are getting more conscious towards personal health care. Personal health care when taken to the next stage would be in such a state where a person can carry on his/her diagnosis by themselves and update them on a database which can be analysed by a trained professional. People go online for almost every commodity, the next stage which could be proposed in the future days to come, is a personal health care system in which initial diagnosis is done in-home. The world health organization in its recent report mentions about traditional and complementary medicine (T&CM) as the most important and often underestimated part of health services [39] .At the international conference on Traditional medicine for south east Asian countries held on February 2013 , Dr. Margaret chan had emphasised on preserving the knowledge about ancient medicines and the practices which is a in house treatment which is affordable to everyone , when the health care cost are soaring in their costs.

Japan is one of countries where technology is in its cutting edge, they share a estimated amount of US$130 billion under research and development , which is considered as the third largest in the world . While mentioning about their technical growth, the article released by WHO[39] quotes the Japanese health insurance and reimbursement in Japan , the article state that 84% of Japanese physicians use Kampo medicines. The main reason to mention kampo medicine is that in traditional Japanese health care (kampo) tongue color is a important aspect in discerning a patients condition[4] .The tongue color variations were studied using Fransworth-Munsell 100 Hue test . The tongue color degraded with the patient age, but the kampo practitioner with more than 10 years of experience is capable of diagnosing the patient condition irrespective of the patient ageing .This paper [1] inspired from the non invasive method of detection, has tried to diagnose if a person has diabetes or is prone to diabetes mellitus or diabetic retinopathy from the image of the tongue. The tongue color, texture and geometry is taken into consideration.

II. ANALYSIS OF THE TONGUE

A. Tongue Diagnosis As Part Of TCM

The tongue is a muscular organ [40] in the mouth .It is covered with a tissue called mucosa , this gives the tongue a pink color .Papillae is responsible for the texture of the tongue , the taste buds cover the papillae and these taste buds are connected to the cells that are in close resemblance to the nerve and they are well connected to the brain , through which the different taste signals are transmitted .The tongue according to the TCM(traditional Chinese medicine) has connection to lost of the internal organs and the channels that

are linked to the tongue . It is the primary organ for inspection and diagnosis in TCM. The tongue is perceived to have special connection with the heart. Beautifully the tongue is described as "flowers" into the heart [41] . The rule is that when one part of the body is affected it is reflected in other parts of the body. The anatomy according to the kampo medicine specifies that the heart channel connects to the tip of the tongue, the spleen channel connects to the lower surface of the tongue, it is said that the spleen divergent channel penetrates the tongue. Kidney channel is said to terminate at the base of the tongue. The liver and gall bladder are interlinked to the roots of the tongue .Taken the physical view of the tongue the connected organs are connected as shown in the Fig.1.

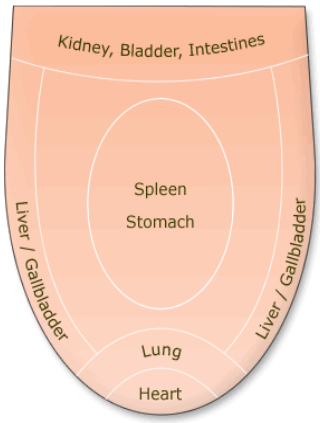

Fig.1. Tongue areas as they correspond to internal organs in chinese medicine.

In the chinese traditional practice the tongue is analysed based on color, shape ,features, moisture ,coating ,tongue coating thickness ,tongue body cracks, tongue coat root.

B. General Tongue Analysis

A normal tongue has a pink or light red color . When the tongue is found to be bluish purple or reddish purple tongue indicates both cold and hot conditions. A reddish purple tongue can be a symptom a heat and blood stagnation .A dark reddish purple color to the tongue may be due to the depleted fluids which may be due to excess heat in the body. A dark red tongue may indicate a dificiency of heat or a excess heat in the person's body. The deficiency or a excess heat can be distinguished from the type of coating on the tongue surface , yellow coating in case of deficiency and a shiny coat , or little or no coat indicates deficient of heat . A red tip of the tongue indicates that there is heat in heart . A dark red color or a crimson indicates a internal injury such as trauma, nutritive problem or irregular blood level.A pale tongue body indicates cold .A green tongue apart from oral candidiasis , may also indicate upper respiratory track infection.

III. METHODOLOGY

A. Tongue Image

This paper [1] inspired from the non invasive method of detection, has tried to diagnose if a person has diabetes or is prone to diabetes mellitus or diabetic retinopathy from the image of the tongue. The tongue color, texture and geometry is taken into consideration Maintaining the Integrity of the Specifications.

B. Image Color Correction

The image color correction is done online when the images are captured .The images that are captured are liable to be different from the actual image due to the harware used to capture the image , light source , lack of proper illumination or even disturbance when the images are captured. Recent CCD cameras are designed with high performing hardware and well designed software , this has a highly refined design of advanced microchips and software which are capable of overcomming the imperfections during the image capture .The 3 CCD cameras give images with high resolution and less noise level.The intial color adjustment happens in the CCD camera , that has a reserved individual values for the 3 primary colors .This is specifically mentioned as medical cameras.

C. Image Analysis

The images that are captured are taken in a database and then analyzed. The patients concern are taken even before taking the images of the tongue in the database, for the analysis I have taken the images from a medical database . The images that are taken are analysed by segmentation process where the foreground pixels of the tongue are separated from the background pixels. The segmentation is done with the help of BEDT(bielliptical deformation template) in combination with the BEDC (bielliptical deformation contour).

D. Tongue Image Diagnosis

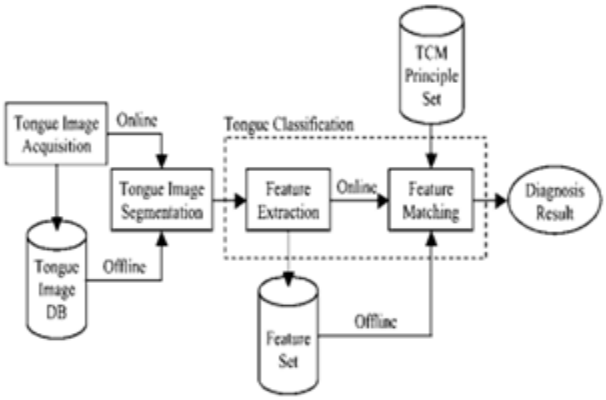

Fig.2. Flowchart of biometric based automatic tongue diagnosis system.

The tongue as a image when analysed has edges which appears as a disconnected section and incomplete regions or so called fragmentary issues along with the pathological details which usually appears on the surface of the tongue. The traditional image processing technique which uses edge detection and region growing fails due to the fragmentary weakness of the edges of the image of the tongue as shown in the Fig.2. The edge detection traces the edges with the help of a function that searches the images where the intensity of the image changes rapidly.

IV. EXPERIMENTAL PROCEDURE TO DIAGNOSE DIABETES AND DIABETIC RETINOPATHY

A. Segmentation

Segmentation is the process of partitioning the image into group of pixels which are homogenous with respect to some

criterion [43]. Different groups must not intersect with each other and adjacent groups must be heterogeneous. Segmentation algorithms are not pixel oriented rather are area oriented. The segmentation will cause splitting of image into connected parts. The image segmentation can be classified based on the type of segmentation that is adopted for the type of image analysis. The image analysis algorithms are based on any one of such procedures.

- Region approach
- Boundary approach
- Edge approach

B. Edge Based Segmentation

The edge based segmentation [43] exploits spatial information based on the edges of a image. Edges correspond to the discontinuities in the homogeneity criterion of the segments. The edge detection is usually done using prewitt, sobel and Laplacian filters. But when considering an edges that are deformable and having variation the typical methods that are used for edge detection will not give a satisfactory effect. The BEDT captures gross shape features by using the steepest decent method on its energy function in the parameter space. The BEDC[16] is derived from the BEDT by substituting template forces for classical internal forces, and can deform to fit local details. This algorithm features fully automatic interpretation of tongue images and a consistent combination of global and local controls via the template force. BEDC to a large set of clinical tongue images.

C. Chromaticity Diagram

A colour gamut in the CIExyY color space depicting the tongue colour gamut inside the red boundary. Furthermore, 98% of the tongue colour gamut can be located within the black boundary as shown in the Fig.3. The CIE chromaticity diagram is the international standard for primary colour. It allows all other colors to be defined as the weighted sum of the primary colours. In the CIE system the RGB values are transformed into trisimulus values which are given by XYZ.

$$\begin{bmatrix} X \\ Y \\ Z \end{bmatrix} = \begin{bmatrix} 0.4124 & 0.3576 & 0.1805 \\ 0.2126 & 0.7152 & 0.0722 \\ 0.0193 & 0.1192 & 0.9505 \end{bmatrix} \begin{bmatrix} R \\ G \\ B \end{bmatrix} \quad (1)$$

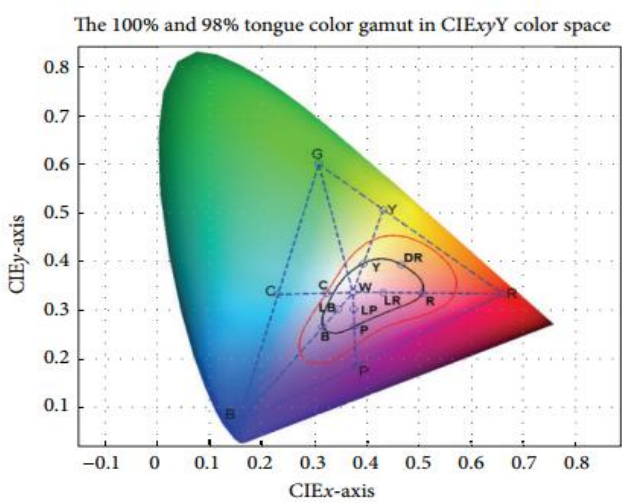

Fig.3. CIExy color space.

The tongue color gamut can be represented using several points by drawing lines from the RGB color space. Colors that are obtained from the color gamut for a normal tongue is given by

Fig.4. Colors of healthy tongue from gamut.

After CIEXYZ we need to convert the same to CIELAB values. From [1]

$$\begin{cases} L = 166.f\left(\frac{Y}{Yo}\right) - 16 \\ a = 500.\left[f\left(\frac{X}{Xo}\right) - f\left(\frac{Y}{Yo}\right)\right] \\ b = 200.\left[f\left(\frac{Y}{Yo}\right) - f\left(\frac{Z}{Zo}\right)\right] \end{cases} \quad (2)$$

Where $f(x)=x^{1/3}$ if $x > 0.008856$ or $f(x)=7.787x+16/116$ if $x \leq 0.008856$.

The LAB values are then compared to 12 colors from the tongue color gamut (see fig.4) and assigned the color which is closest to it (measured using Euclidean distance).After evaluating all tongue foreground pixels, the total of each color is summed and divided by the total number of pixels. This ratio of the 12 colors forms the tongue color feature vector V, where the v is given by v=[c1,c2,c3,c4,c5,c6, c7,c8,c9,c10,c11,c12] [1] and c_i represents the sequence of colors in figure 4. As an example, the color features of three tongues are shown in visual form along with its extracted color feature vector, where the original image is decomposed into one of the 12 colors.

D. Geometry Analysis

In the following subsection we describe the 13 geometry features extracted from tongue images[1].These features based on measurements, distances, areas, and their ratios are used in subsequent sections to define and classify 5 tongue shapes[44].

Width: The width (w) feature is measured as the horizontal distance along the -axis from a tongue's furthest right edge point (x_{max}) to its furthest left edge point(x_{min})[44]

$$W=X_{max} - X_{min} \quad (3)$$

Length: The length (l) features is measured as the vertical distance along the y-axis from a tongue's furthest bottom edge (Y_{max}) point to its furthest top edge point (Y_{min})[44]

$$L= Y_{max} - Y_{min} \quad (4)$$

Length Width Ratio: The length width ratio is given by (lw) ratio[44]

$$Lw = l/w \quad (5)$$

Smaller Half Distance: The smaller half distance (z) is the half distance of l or w depending on which segment is shorter[44]

$$Z = \frac{\min(l,w)}{2} \quad (6)$$

Center Distance: The center distance cd refers to the distance from w's y-center point to the center point of l(y_{cp})[44]

$$Cd = \frac{(\max(yxmax) + \max(ymin))}{2} - y_{cp} \quad (7)$$

Center Distance Ratio: Center Distance Ratio. Center distance ratio (cdr) is ratio of cd to l [44]

$$cdr = cd\,l \quad (8)$$

Area: The area (a) of a tongue is defined as the number of tongue foreground pixels[44].

Circle Area: Circle area (ca) is the area of a circle within the tongue foreground using smaller half Distance$z$,where[44]

$$r = z \quad (9)$$

$$ca = \pi r^2 \quad (10)$$

Circle Area Ratio: Circle area ratio (car) is the ratio of ca to a [44]

$$car = ca/\,a \quad (11)$$

Square Area: Square area (sa) is the area of a square defined within the tongue foreground using smaller half distance Z[44]

$$sa = 4z^2 \quad (12)$$

Square Area Ratio: Square area ratio (sar) is the ratio of sa to$a$[44]

$$sar = \frac{sa}{a} \quad (13)$$

Triangle Area: Triangle area (t_a) is the area of a triangle defined within the tongue foreground .The right point of the triangle is $x$max, the left point is $x$min and the bottom is$y$max.[44]

Triangle Area Ratio: Triangle area ratio (tar) is the ratio of t_a to a:

$$tar = \frac{ta}{a} \quad (14)$$

Tongue Shape Classification on TCM we can define 5 tongue shapes, rectangle, acute triangle, obtuse triangle, square, and circle, which can be classified using the 13 features explained [44].A rectangle tongue's vertical length is long, but its horizontal width along the tip, body, and root remains relatively constant. An acute triangle tongue's vertical length is longer than its largest horizontal width (at the root) but gradually decreases from the body down to the tip .If the tongue shape is an obtuse triangle ,its horizontal width is greater than its vertical length, with the width steadily decreasing as it approaches the tip. In a square tongue shape both its horizontal width and vertical length are similar. Finally, if a tongue is circle, both the horizontal width and vertical length will be alike. To classify tongue images into its proper shape, a decision tree structure shown in Fig.5 is used. Given a tongue[44] we first examine its length-width (lw) ratio. If this ratio is $tlw_{low} \le l_w \le tlw_{high}$, the tongue shape must be square or circle(left branch), and if the ratio is $tlw_{high} < lw$ or $tlw_{low} > l_w$, the shape of the tongue can be rectangular ,acute triangle or obtuse triangle (right branch). The values of tlw_{low} and tlw_{high} are 0.95 and 1.05,respectively. Focusing on the left branch, the average radius (r_{avg})of the tongue is first calculated as

$$R_{avg} = \frac{(l+w)}{4} \quad (15)$$

The ratio of T_{sc} is calculated as

$$T_{sc} = a/R_{avg}^2 \quad (16)$$

If the tongue shape is approximately square, the value of$T$sc ≈ 4(i.e.,$4 \cdot R_{avg}^2/R_{avg}^2$), and if it is approximately circle,$T_{sc} \approx \pi$ i.e.,$\pi \cdot R_{avg}^2/R_{avg}^2$). Hence, the two shapes can be defined as Square=Tsc $\ge \pi+\varepsilon$, Circle=$T_{sc} < \pi+\varepsilon$.Turning our attention to the right branch, we initially calculate the ratio T_{rao} : $T_{rao} = a(l \cdot w)$ If this ratio is greater than or equal to t_{rect} ,the tongue shape is rectangle Rectangle=Trao$\ge t$rect where t_{rect} is 0.85 and the maximum of T_{rao} is 1[44]. If $T_{rao} < t_{rect}$t, the shape of the tongue is either acute or obtuse triangle. To determine which triangle, length-width ratio is used once again as follows[44]

Acute Triangle =($T_{rao} < t_{rect}$)$\wedge$($l_w \ge t_{ao}$)
Obtuse Triangle=($T_{rao} < t_{rect}$)$\wedge$($lw < t_{ao}$ 05.

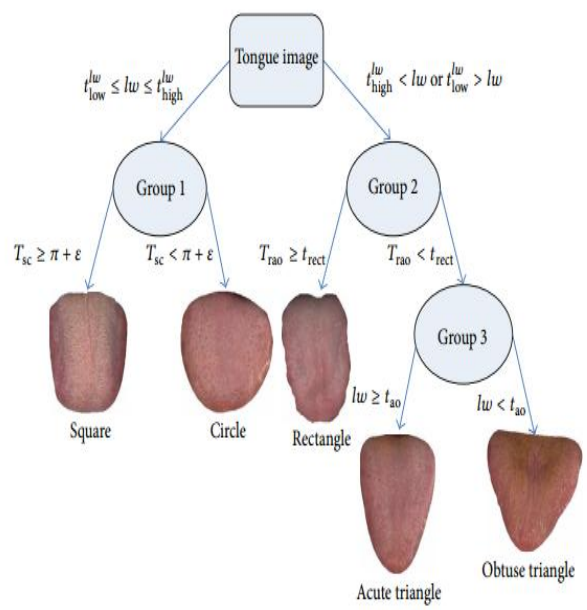

Fig.5.Decision tree to classify the tongue shapes.

V. EXPERIMENT AND RESULTS

A. Tongue Color Analysis

The tongue image is obtained from the list of database data and they are analyzed by the methodology specified in the section III. The tongue image taken is given and the result of matlab simulation is given which shows that most of the image lies in the bluish region for a non healthy tongue as shown in the Fig.6.

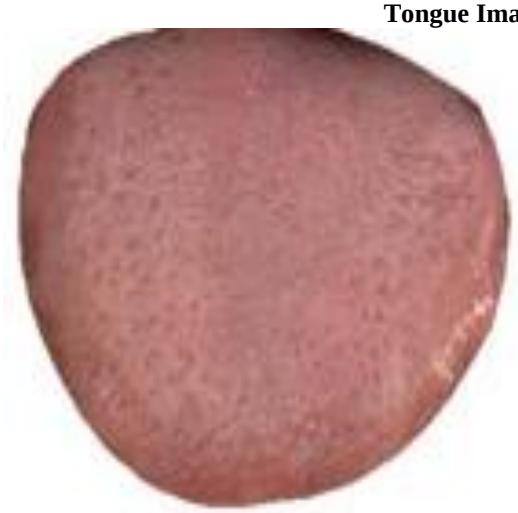

Fig.6. Tongue image.



Fig.7.simulated color analysis.

Fig.7 shows matlab output corresponding to Lab values of the image.

B. Expected Values

TABLE I: Expected Values

	R	DR	LR	BK	GY	W	Y
healthy	20.92	5.66	33.84	8.235	14.55	7.91	8.048
Disease	28.29	15.59	11.02	15.43	16.22	2.499	10.63

The values are taken as a basis to identify if a tongue is a indication of the diseases. These 12 color comparison with the 13 geometry feature is used to identify if a person is suffering from medical disorder. Similarly the tongue geometry features are considered and the analysis show that the geometry could prove the presence of diabetes mellitus and non proliferative diabetic mellitus.

TABLE II:

	D1	D2	H1	H2	H3
w	243	151	168	162	175
l	237	192	145	139	134
lw	0.953	1.2715	0.8631	0.858	0.7657
z	118.5	75.5	72.5	69.5	67
cd	5	-17.5	11.5	13.5	20
cdr	0.0211	-0.0911	0.0793	0.0971	0.1493
a	39938	16050	14809	14880	14516
ca	4.41E+04	1.79E+04	1.65E+04	1.52E+04	1.41E+04
car	1.1046	1.1158	1.1151	1.0198	0.9715
sa	56169	22801	21025	19321	17956
sar	1.4064	1.4206	1.4197	1.2985	1.237
ta	14889	8196	5140	5286	5768
tar	0.3728	0.5107	0.3471	0.3552	0.3974

VI. FUTURE WORK

The tongue texture analysis is also considered to obtain a even more precise detection of the presence of the disease . Once the texture values are obtained it is compared with the healthy tongue values, and taking the entire 32 feature the advanced detection of the disease is done.

VII .REFERENCES

[1] Detecting diabetes mellitus and Nonproliferative diabetic retinopathy using Tongue color , Texture , and Geometry features. Bob Zhang, Vijaya Kumar and David Zhang.
[2]http://www.medicalnewstoday.com/info/diabetes.
[3] http://en.wikipedia.org/wiki/Kampo.
[4] Study of Factors Involved in Tongue Color Diagnosis by Kampo Medical Practitioners Using the Farnsworth-Munsell 100 Hue Test and Tongue Color Images , Takeshi Oji,Takao Namiki,Toshiya Nakaguchi,Keigo Ueda, Kanako Takeda, Michimi Nakamura,Hideki Okamoto,and Yoshiro Hirasaki. Hindawi Publishing Corporation, Volume 2014, Article ID 783102.
[5]http://en.wikipedia.org/wiki/Diabetic_retinopathy.
[6] Chiu CC. Development of a computerized tongue diagnosis system. Biomedical Engineering.1996;8(4):342–350.
[7] Chiu CC. A novel approach based on computerized image analysis for traditional Chinese medical diagnosis of the tongue. Computer Methods and Programs in Biomedicine. 2000;61(2):77–89. [PubMed].
[8] Duda RO, Hart PE, Stork DG. Pattern Classification. 2nd edition. Wiley & Sons; 2000.
[9] Kirschbaum B. Atlas of Chinese Tongue Diagnosis. Seattle, Wash, USA: Eastland Press; 2000.
[10] Li B, Huang Q, Lu Y, Chen S, Liang R, Wang Z. A method of classifying tongue colors for traditional chinese medicine diagnosis based on the CIELAB color space. Proceedings of the International Conference on Medical Biometrics; 2007; pp. 153–159.
[11] Li CH, Yuen PC. Tongue image matching using color content. Pattern Recognition. 2002;35(2):407–419.
[12] Li NM. The Handbook of Chinese Tongue Diagnosis.Shed-Yuan Publishing; 1994.The contemporary investigations of computerized tongue diagnosis.
[21]Zhang, H., Wang, K., Zhang, D., Pang, B., Huang, B.

2005. Computer aided tongue diagnosis system. The 27th IEEE International Conference of Engineering in Medicine and Biology Society.

[22] Kanawong, R., Xu, W., Xu, D., Li, S., Ma, T., and Duan,Y.2012. An automatic tongue detection and segmentation framework for computer-aided tongue image analysis.Int. J. of Functional Informatics and Personalised Medicine.Vol. 4, No. 1, pp.56-68.

[23] Wang, X. and Zhang, D. 2013. A high quality color imaging system for computerized tongue image analysis. Expert Systems with Applications. Vol. 40, No. 15, pp. 5854-5866.

[24] Kanawong, R. 2012. Computer-aided tongue image diagnosis and analysis. Doctoral Dissertation, University of Missouri at Columbia Columbia, MO.

[25] Lo, L.-C., Cheng, T.-L., Chen, W.-J., Chen, Y.-F., and Chiang, J. Y. 2012. The Study on the Agreement between Automatic Tongue Diagnosis System and Traditional Chinese Medicine Practitioners.European Congress for Integrative Medicine (ECIM 2012).

[26] T. McInerney and D. Terzopoulos, "Deformable models in medical image analysis: A survey," Med. Image Anal., vol. 1, no. 2, pp. 91–108, 1996.

[27] M. Kass, A. Witkin, and D. Terzopoulos, "Snakes: Active contour models," in Proc. Int. Conf. Computer Vision, 1987, pp. 259–269.

[28] T. McInerney and D. Terzopoulos, "Topologically adaptable snakes," in Proc. Int. Conf. Computer Vision, 1995, pp. 840–845.

[29] K. F. Lai and R. T. Chin, "On regularization, formulation and initializa- tion of the active contour models (snakes)," in Proc. Asian Conf. Com- puter Vision, 1993, pp. 542–545.

[30] S. R. Gunn and M. S. Nixon, "A robust snake implementation: A dual active contour," IEEE Trans. Pattern Anal. Machine Intell., vol. 19, no. 1, pp. 63–68, Jan. 1997.

[31] C. Y. Xu and J. L. Prince, "Snakes, shapes, and gradient vector flow," IEEE Trans. Image Processing, no. 3, pp. 359–369, Mar. 1998.

[32] B. R. Lee, A. B. Hamza, and H. Krim, "An active contour model for image segmentation: A variational perspective," in IEEE Int. Conf. Acoustics, Speech, Signal Processing, vol. 2, 2002, pp. 1585–1588.

[33] W. N. Lie and C. C. Chuang, "Fast and accurate snake model for object contour detection," Electron.Lett., vol. 37, no. 10, pp. 624–626, May 2001.

[34] H. W. Park, T. Schoepflin, and Y. Kim, "Active contour model with gra- dient directional information: Directional snake," IEEE Trans. Circuits Syst. Video Technol., vol. 11, no. 2, pp. 252–256, Feb. 2001.

[35] V. Caselles, R. Kimmel, and G. Sapiro, "Geodesic active contours," in Proc. Int. Conf. Computer Vision, Cambridge, MA, 1995, pp. 694–699.

[36] D. Terzopoulos and D. Metaxas, "Dynamic 3D models with local and global deformations: Deformable superquadrics," IEEE Trans. PatternAnal. Machine Intell., vol. 13, no.7,pp.703–714,Jul.1991.

[37] D. Metaxas and D. Terzopoulos, "Shape and nonrigid motion estimation through physics-based synthesis," IEEE Trans. Pattern Anal. Machine Intell., vol. 15, no. 6, pp. 580–591, Jun. 1993.

[38] Tongue Color Analysis for Medical Application, Bob zhang , Xingzheng Wang ,Jane you, and David Zhang , Hindwai Publishing corporation , volume 2013 , Article ID 264742.

[39] world traditional medical statergy 2014-2015 ISBN 978 9241506090, http://apps.who.int/iris/bitstream/10665/ 92455/ 1/9789241506090_eng.pdf.

[40]http://www.webmd.com/oral-health/picture-of-thetongue.

[41]http://www.sacredlotus.com/go/diagnosis-chinese-medicine/get/tongue-diagnosis-chinese-medicine.

[42]http://www.oooojournal.net/article/S1079-2104%2800%2936842-1/pdf.

[43] Digital image processing by S Jayaraman, S Esakkirajan, T Veerakumar.

[44] Bob Zhang and Han Zhang ,"Significant geometry features in Tongue Image analysis".